



Patient	NHS No
D.O.B.	Patient Ref
Reason	Varicose vein
Outcome	Incompetence

	Right		Left	
Deep Veins	Patency	Competency	Patency	Competency
Common Iliac Vein				
External Iliac Vein				
Internal Iliac Vein				
Common Femoral Vein	Widely Patent	Competent		
Profunda Vein				
Superficial Femoral Vein				
Popliteal Vein	Widely Patent	Competent		
Posterior Tibial Vein				
Anterior Tibial Vein				
Peroneal Vein				
Soleal Vein				
Gastrocnemius				
Superficial Veins				
Saphenofemoral Junction	Widely Patent	Incompetent		
L Saphenous Vein Above	Widely Patent	Isolated Incompetence		
L Saphenous Vein Below	Widely Patent	Competent		
Vein of Giacomini	Widely Patent	Competent		
Saphenopopiteal Junction	Not Identified			
S Saphenous Vein	Widely Patent	Competent		
Evidence of D.V.T.				
Above the knee	No			
Popliteal	No			
Below the knee				

## Notes

### RIGHT LOWER LIMB VENOUS DUPLEX ASSESSMENT

Iliac veins not viewed. Flow in the common femoral vein is phasic with respiration and a normal response on Valsalva manoeuvre, suggesting proximal vein patency. Common femoral and popliteal veins are widely patent and competent with no evidence of DVT.

Sapheno-femoral junction (SFJ) is incompetent. Long saphenous vein (LSV) is incompetent and linear in the thigh. Incompetent branch leaves the LSV in the distal thigh and forms the visible varicosities of the prox / mid calf. Distal to this branch the LSV is competent.

Transverse (AP) dimensions of LSV: proximal thigh 0.63cm, mid-distal thigh 0.43cm.

Sapheno-popliteal junction (SPJ) was not identified. Short saphenous vein (SSV) is competent and is

Assessed by	Lukasz Koprowski	Checked by	
-------------	------------------	------------	--



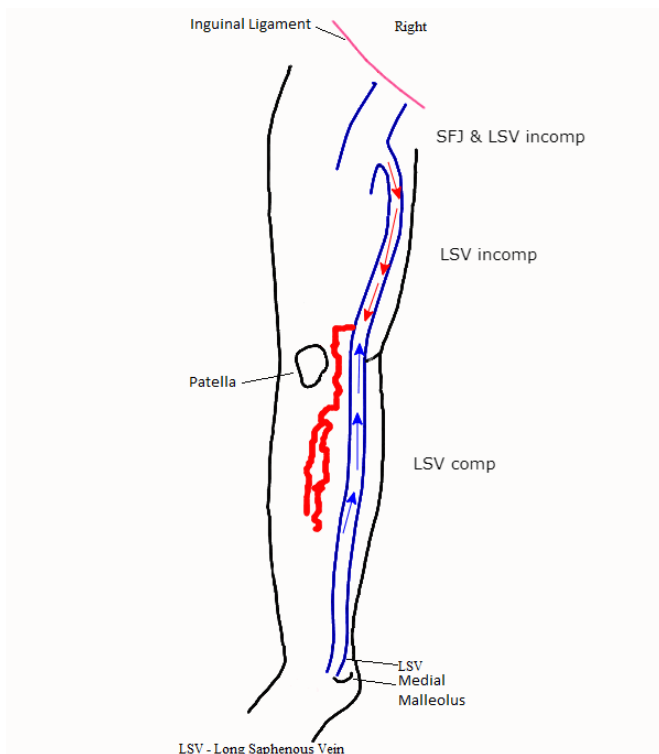
Patient

NHS No

D.O.B.

Patient Ref

continuous with a competent vein of Giacomini.



Assessed by

Lukasz Koprowski

Checked by